



**COVID-19 and tuberculosis (TB): Be alert for these overlapping syndromes!**

Consider TB disease as a cause of respiratory illness – even in those who test positive for COVID-19 – when TB risks, signs, symptoms or imaging findings below are present.

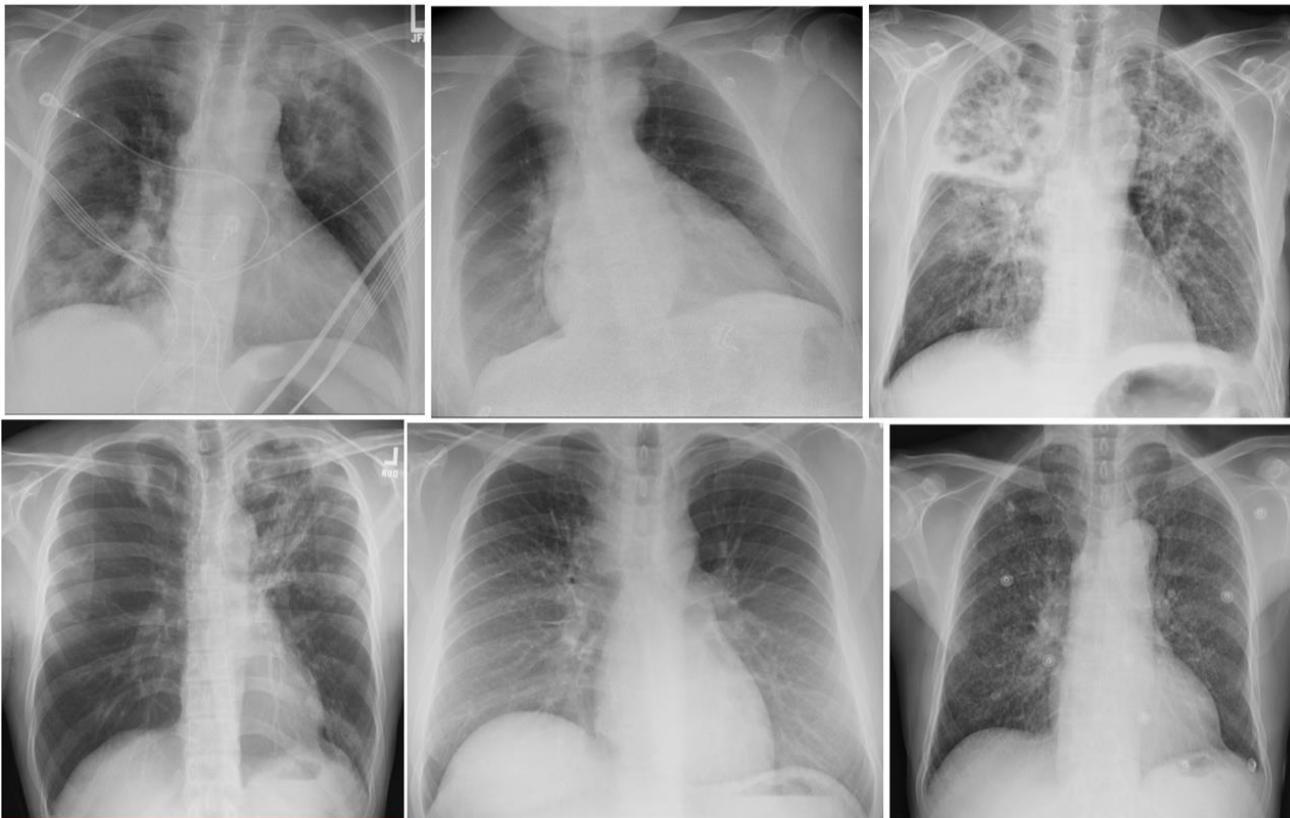
**Risks for TB disease:**

- Lived outside the United States
- Immunocompromised
- Close contact to someone with TB disease

**Signs and symptoms more consistent with TB disease:**

- Persistent cough  $\geq 3$  weeks
- Weight loss
- Hemoptysis

Imaging findings of TB disease: The appearance of active TB is highly variable, and certain imaging findings overlap with those often present in COVID-19. Below are six chest x-rays of patients with TB disease:



Findings of TB disease (clockwise from top left): cavitory consolidation, pleural effusion, consolidation and bronchiectasis, miliary nodules, lymphadenopathy (widened right paratracheal stripe), apical scarring and cavities.

**Call to report suspected or confirmed TB: (628) 206-3398**

Health Alert: <https://www.sfgdcp.org/health-alerts-emergencies/health-alerts/>

**San Francisco General Hospital TB Clinic • Ward 94  
1001 Potrero Avenue, San Francisco, CA 94110**

**Report TB: (628) 206-3398 • Clinic: (628) 206-8524 • Fax: (628) 206-4565 • [www.sfgdcp.org/tb-control](http://www.sfgdcp.org/tb-control)**